The American Society of Colon and Rectal Surgeons Clinical Practice Guidelines for the Management of Inherited Adenomatous Polyposis Syndromes

Vitaliy Y. Poylin, M.D., M.B.A.[1] • Virginia O. Shaffer, M.D.[2] • Seth I. Felder, M.D.[3]
Lindsey E. Goldstein, M.D.[4] • Joel E. Goldberg, M.D., M.P.H.[5] • Matthew F. Kalady, M.D.[6]
Amy L. Lightner, M.D.[7] • Daniel L. Feingold, M.D.[8] • Ian M. Paquette, M.D.[9]

On Behalf of the Clinical Practice Guidelines Committee of the American Society of Colon and Rectal Surgeons

1 Division of Gastrointestinal and Oncologic Surgery, Northwestern University Feinberg School of Medicine, Chicago, Illinois
2 Department of Surgery, Emory University College of Medicine, Atlanta, Georgia
3 Department of Surgery, Moffit Cancer Center, Tampa, Florida
4 Division of General Surgery, North Florida/South Georgia Veteran's Health System, Gainesville, Florida
5 Division of General and Gastrointestinal Surgery, Brigham and Women's Hospital, Harvard Medical School, Boston, Massachusetts
6 Division of Colon and Rectal Surgery, Ohio State University, Columbus, Ohio
7 Department of Colorectal Surgery, Scripps Clinic, San Diego, California
8 Division of Colorectal Surgery, Rutgers University, New Brunswick, New Jersey
9 Division of Colon and Rectal Surgery, University of Cincinnati, Cincinnati, Ohio

The American Society of Colon and Rectal Surgeons (ASCRS) is dedicated to ensuring high-quality patient care by advancing the science, prevention, and management of disorders and diseases of the colon, rectum, and anus. The Clinical Practice Guidelines Committee is composed of society members who have been chosen because they have demonstrated expertise in the specialty of colon and rectal surgery. This committee was created to lead international efforts in defining quality care for conditions related to the colon, rectum, and anus and develop clinical practice guidelines based on the best available evidence. Although not proscriptive, these guidelines provide information on which decisions can be made and do not dictate a specific form of treatment. These guidelines are intended for the use of all practitioners, health care workers, and patients who desire information about the management of the conditions addressed by the topics covered in these guidelines. These guidelines should not be deemed inclusive of all proper methods of care nor exclusive of methods of care reasonably directed toward obtaining the same results. The ultimate judgment regarding the propriety of any specific procedure must be made by the physician in light of all the circumstances presented by the individual patient.

STATEMENT OF THE PROBLEM

Approximately 20% to 30% of patients with colorectal cancer have a family history of colorectal polyps or cancer, and approximately 5% to 10% of cases are associated with an identifiable inherited colorectal cancer syndrome.[1,2] The most recognizable polyposis syndromes, familial adenomatous polyposis (FAP), has an impressive phenotype that typically includes thousands of adenomatous polyps.[3,4] FAP is an autosomal dominant syndrome with close to 100% penetrance that progresses to colorectal cancer unless treated. Patients with FAP also have a lifetime risk of developing extracolonic manifestations and other malignancies such as gastric, duodenal, pancreatic, thyroid, brain, and desmoid tumors. A constitutional pathogenic variant of the adenomatous polyposis coli (*APC*) tumor suppressor gene located on chromosome 5q21 is identified in most patients with FAP.[5,6] Hypermethylation of the *APC* promotor 1B has also been associated with polyposis.[7]

CME

Earn Continuing Education (CME) credit online at cme.lww.com. This activity has been approved for AMA PRA Category Credit.™

Funding/Support: None reported.

Financial Disclosure: None reported.

Correspondence: Ian M. Paquette, M.D., Division of Colon and Rectal Surgery, University of Cincinnati College of Medicine (Colon and Rectal), 2123 Auburn Ave #524, Cincinnati, OH 45219. E-mail: ian.m.paquette@gmail.com

Dis Colon Rectum 2024; 67: 213–227
DOI: 10.1097/DCR.0000000000003072
© The ASCRS 2023

Copyright © The American Society of Colon & Rectal Surgeons, Inc. Unauthorized reproduction of this article is prohibited.
<zjs:CLINICAL PRACTICE GUIDELINES> • <zjXXX> • <zdoi:10.1097/DCR.0000000000003072>

However, up to 25% of newly diagnosed patients with FAP do not have a contributory family history; these probands develop FAP through a de novo variant or mosaicism.[6,8]

Generally, pathogenic variants between codons 169 and 1393 are associated with classic FAP, and pathogenic variants 5′ (5′ to codon 158) and 3′ (3′ to codon 1596) ends of the *APC* gene are associated with a clinical phenotype of less colonic polyps.[9] Alternatively, a subset of adenomatous polyposis caused by biallelic constitutional pathogenic variants of the base excision-repair gene MutY homolog (*MYH*) results in an autosomal recessive syndrome termed *MYH*-associated polyposis (MAP).[4,10]

Despite advances in genetic testing, a significant number of patients with polyposis have no identifiable pathogenic variant. This clinical practice guideline will review the diagnosis and management of FAP, *MUTYH*, adenomatous polyposis associated with other genes, adenomatous polyposis without an identified genotype, and the extraintestinal manifestations associated with adenomatous polyposis syndromes. Hereditary nonpolyposis colorectal cancer is covered in a separate clinical practice guideline.

METHODOLOGY

This guideline is an update of the previously published "Clinical Practice Guidelines for the Management of Inherited Polyposis Syndromes," published in 2017.[1] An organized, systematic search of MEDLINE, PubMed, Embase, Web of Science, and the Cochrane Database of Collected Reviews was performed, and studies published between December 1, 2016, and February 1, 2023 were included. Key-word combinations included "hereditary" or "inherited" or "genetic" or "familial" AND "rectal" or "colon" or "intestine" or "intestinal" or "rectum" or "colorectal" AND "adenomatous polyposis coli" or "polyposis" or "adenoma" or "*MYH*-associated polyposis" or "desmoid" or "fibromatosis" or "serrated polyposis" or "polyposis syndromes" or "FAP" or "MUTYH" or "MYH" OR "adenomatous polyposis coli"[MeSH] or "intestinal polyposis"[MeSH] or "fibromatosis, aggressive"[MeSH] or "adenomatous polyposis coli protein"[MeSH]. The search was limited to the English language, and only abstracts and reports with human subjects were included. Emphasis was placed on prospective trials, meta-analyses, systematic reviews, and practice guidelines. Peer-reviewed observational studies and retrospective studies were included when higher-quality evidence was insufficient. Briefly, a total of 17,119 titles were identified after excluding 8491 duplicates, and 8628 titles and abstracts were reviewed. Overall, 6356 articles were excluded for the following reasons: they were commentaries, letters, irrelevant, unrelated, case reports, duplicate publications, or had no available abstract. A total of 2272 articles were screened, and 2180 were excluded because of the availability of higher-level evidence. Additional articles were added from the previous ASCRS Guidelines, directed searches of embedded references from primary articles, and from manuscripts identified by individual authors; a total of 154 articles were included in the final document (Fig. 1).

CERTAINTY OF EVIDENCE

The final grade of recommendation and level of evidence for each statement were determined using the Grades of Recommendation, Assessment, Development, and Evaluation (GRADE) system.[11] The certainty of evidence reflects the extent of our confidence in the estimates of effect. Evidence from randomized controlled trials (RCTs) starts as high certainty and evidence derived from observational studies starts as low certainty. For each outcome, the evidence is graded as high, moderate, low, or very low (Table 1). The evidence can be rated down for risk of bias, inconsistency, indirectness, imprecision, and publication bias. The certainty of evidence originating from observational studies can be rated up when there is a large magnitude of effect or dose–response relationship. As per GRADE methodology, recommendations are labeled as "strong" or "conditional." A summary of recommendations and GRADE of evidence is included in Table 2. When agreement was incomplete regarding the evidence base or treatment guideline, consensus from the committee chair, vice chair, and 2 assigned reviewers determined the outcome. Recommendations formulated by the subcommittee were reviewed by the entire Clinical Practice Guidelines Committee. The submission was then approved by the ASCRS Executive Council and peer-reviewed in *Diseases of the Colon and Rectum*. Each ASCRS Clinical Practice Guideline is generally updated approximately every 5 years. No funding was received for preparing this guideline, and the authors have declared no competing interests related to this material. This guideline conforms to the Appraisal of Guidelines for Research and Evaluation checklist.

RECOMMENDATIONS

Screening and Genetic Testing for Adenomatous Polyposis Syndromes

1. Polyposis syndromes should typically be considered in patients with greater than 10-lifetime adenomas, colorectal cancer diagnosed at an age younger than 50 years, a personal history of desmoid disease or other extracolonic manifestations of polyposis syndromes, or with family members with known FAP or MAP. Strength of recommendation: strong based on moderate-quality evidence.

FAP, defined as having more than 100 synchronous colorectal adenomas, is inherited in an autosomal dominant manner from constitutional pathogenic variants of the *APC* gene.[12–14]

Copyright © The American Society of Colon & Rectal Surgeons, Inc. Unauthorized reproduction of this article is prohibited.

Historically, patients with more than 100 adenomas found on colonoscopy are typically given a clinical diagnosis of polyposis. However, polyp formation is an age-dependent phenomenon, and patients with fewer adenomas or a family history suggestive of polyposis should undergo genetic testing.[2] Guidelines recommend genetic testing for individuals with greater than 10 to 20 cumulative lifetime adenomas as patients with more than 20 adenomas have a more than 10% risk of carrying a genetic pathologic variant.[4,15] In a 2012 cross-sectional

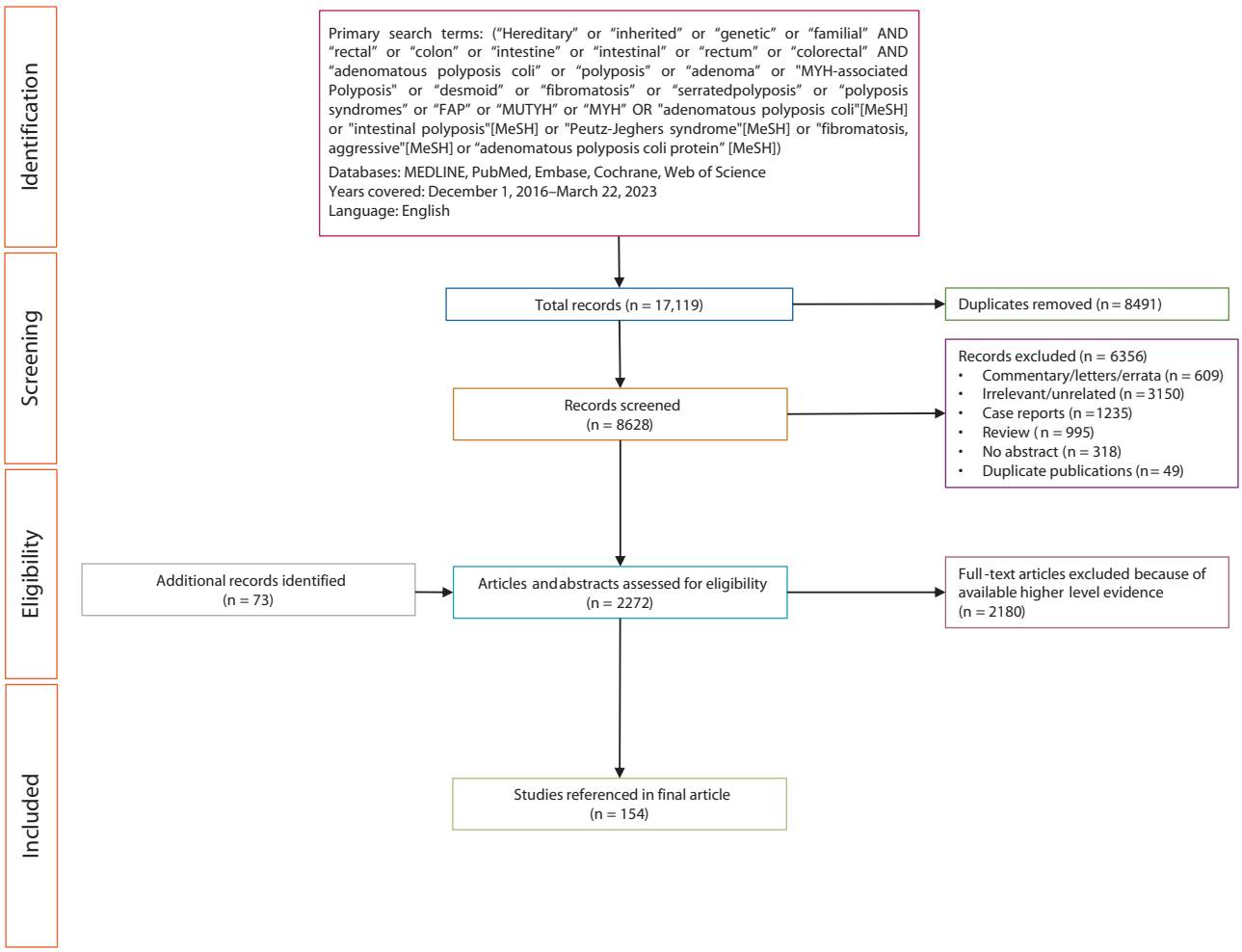

FIGURE 1. PRISMA literature search flow chart. PRISMA = Preferred Reporting Item for Systematic Reviews and Meta-Analysis.

TABLE 1. Interpretation of strong and conditional recommendations using the GRADE approach

Evaluation	*Description*
Recommendation	
Strong	Most individuals should receive the intervention. Formal decision aids are not likely to be needed to help individuals make decisions consistent with their values and preferences.
Conditional	Different choices will be appropriate for individual patients, consistent with their values and preferences. Use shared decision-making. Decision aids may be useful in helping patients make decisions consistent with their individual risks, values, and preferences.
GRADE certainty rankings	
High	The authors are confident that the true effect is similar to the estimated effect.
Moderate	The authors believe that the true effect is probably close to the estimated effect.
Low	The true effect might be markedly different from the estimated effect.
Very low	The true effect is probably markedly different from the estimated effect.

GRADE = Grading of Recommendations, Assessments, Development, and Evaluation.

Copyright © The American Society of Colon & Rectal Surgeons, Inc. Unauthorized reproduction of this article is prohibited.

TABLE 2. Summary and strength of GRADE recommendations

	Summary	*Recommendation strength*	*GRADE quality of evidence*
1	Polyposis syndromes should typically be considered in patients with greater than 10-lifetime adenomas, with colorectal cancer diagnosed at an age younger than 50 years, a personal history of desmoid disease or other extracolonic manifestations of polyposis syndromes, or with family members with known FAP or MAP.	Strong	Moderate
2	Management of patients with a suspected adenomatous polyposis syndrome should include a thorough family history, referral to genetic counseling, and testing with a multigene panel.	Strong	Moderate
3	At-risk family members of a polyposis patient with an identified pathogenic variant should typically undergo testing for the known familial pathologic variant.	Strong	Low
4	Total abdominal colectomy with ileorectal anastomosis can be offered to FAP patients with relative rectal sparing if all rectal adenomas of >5 mm size can be endoscopically removed. Proctocolectomy with ileostomy or IPAA is the treatment of choice for patients with a rectal adenoma that cannot be managed endoscopically.	Conditional	Low
5	Screening for duodenal adenomas in patients with FAP should begin with a baseline esophagogastroduodenoscopy at the age of 20 to 25 years, and subsequent examinations should be performed at intervals based on endoscopic findings.	Strong	Low
6	Patients with FAP are at increased risk of thyroid cancer and may undergo thyroid cancer screening with annual physical examination and ultrasound starting in the late teens.	Conditional	Very low
7	Patients with biallelic *MUTYH* pathogenic variants should typically undergo yearly colonoscopy if the adenoma burden can be cleared endoscopically. First-degree relatives of an affected individual are recommended to undergo genetic counseling and testing for *MUTYH*.	Conditional	Low
8	The timing and extent of resection recommended for patients with biallelic *MUTYH* pathogenic variants depend on the ability to clear polyps, the rectal polyp burden, and the presence of malignancy.	Conditional	Very low
9	In patients with MAP, upper endoscopy is recommended beginning at the age of 30 years, with subsequent examinations at intervals based on the endoscopic findings.	Conditional	Very low
10	Patients with FAP or MAP with retained colon or rectum may be considered for chemoprevention for adenomas.	Conditional	High
11	Pharmacologic treatment, rather than surgery, is the preferred initial approach for patients with polyposis-associated intra-abdominal desmoid disease.	Strong	Moderate
12	Surgery for intra-abdominal desmoid tumors should typically be reserved for symptomatic patients not responsive to medical therapy.	Conditional	Low
13	Patients with clinical polyposis, but without an identified pathogenic variant, should be managed on the basis of their phenotype.	Conditional	Very low

FAP = familial adenomatous polyposis; GRADE = Grading of Recommendations, Assessments, Development, and Evaluation; MAP = MutY homolog–associated polyposis.

study of 8903 patients who had samples submitted for *APC* and *MYH* pathologic variant analysis, pathogenic variants were identified in 82% of patients with more than 1000 polyps, 63% of patients with 100 to 999 polyps, 17% of patients with 20 to 99 polyps, and 9% of patients with 10 to 19 polyps.[10] In addition, having colorectal cancer diagnosed before the age of 50 years increases the risk of having a constitutional pathogenic variant and should prompt genetic testing.[16–20] In a prospective study of 450 patients with colorectal cancer before the age of 50 years, 72 (16%) had an identifiable pathologic variant that prompted a change in management.[16]

Importantly, a family history of polyposis is not required to pursue genetic testing because the absence of a family history of polyposis or colorectal cancer does not exclude the diagnosis of a polyposis syndrome; de novo pathogenic variants in the *APC* gene may occur in up to 25% of patients with FAP, and MAP is recessively inherited.[21,22] In a family with clinical FAP but no identifiable pathologic variant in *APC*, screening and treatment should follow the same principles as those recommended for patients with proven pathogenic variants.

2. Management of patients with a suspected adenomatous polyposis syndrome should include a thorough family history, referral to genetic counseling, and testing with a multigene panel. Strength of recommendation: strong based on moderate-quality evidence.

Pre- and posttest genetic counseling is recommended for patients with, or suspected of having, an adenomatous polyposis syndrome.[4,23–25] Personal and family histories, as well as testing options and potential outcomes, should be reviewed before undertaking genetic testing.[18] If testing is pursued, genetic counselors should provide education about the logistics and implications of testing.[26] Posttest

Copyright © The American Society of Colon & Rectal Surgeons, Inc. Unauthorized reproduction of this article is prohibited.

counseling involves reviewing the meaning of the genetic test results and the practical and clinical implications for the patient and at-risk family members. Counselors can also support testing at-risk family members (ie, cascade testing) and facilitate multidisciplinary care based on the polyposis phenotype.[27] Ideally, patients and family members should participate in a registry screening program. In a meta-analysis by Barrow et al,[28] all 33 studies reviewed showed a significant decrease in colorectal cancer incidence (by 79%) and mortality (by 59%) in families referred to genetic registries and counseling. Nonetheless, studies continue to report low rates of referrals to these registries and underutilization of genetic counseling in general.[29] For example, a cross-sectional multicenter study in the United Kingdom found that only 28 of 347 patients with 10 or more adenomas (8.1%) who qualified for testing were actually referred for assessment.[30]

When there is a clinical suspicion for an adenomatous polyposis syndrome, patients should be tested for constitutional pathogenic variants with a multigene panel because testing for only *APC* and *MUTYH* genes may miss some cases of polyposis.[10,31] Patients with a cumulative lifetime incidence of at least 20 adenomas without a genetic abnormality are classified as having colonic polyposis of unknown cause. Multigene testing is important because in addition to the classic *APC* pathogenic variants, there are pathogenic variants in *NTHL*-1, *AXIN*, constitutional mismatch repair disorder, polymerase proofreading-associated polyposis, and *MSH3*-associated polyposis that can all lead to the clinical phenotype of adenomatous polyposis. If genetic testing is unavailable, screening family members for extraintestinal manifestations, such as dental abnormalities, osteomas, and soft tissue tumors of congenital hypertrophy of the retinal pigment epithelium, should also be performed.

3. At-risk family members of a polyposis patient with an identified pathologic variant should typically undergo testing for the known familial pathogenic variant. Strength of recommendation: strong based on low-quality evidence.

When a patient is the first in a family to be diagnosed with FAP (ie, the proband), genetic testing is indicated. If a pathogenic variant is found, at-risk relatives of the proband should be screened for the same pathogenic variant. This directed screening approach is more affordable and quicker compared with screening using multigene panel sequencing. Most guidelines recommend initiating testing in children at puberty because the risk of developing cancer is considered to be low before this age. Overall, colorectal cancer risk is nearly 100%, with an average age of diagnosis being 39 years. According to observational data, colorectal cancer has not been reported before the age of 9 years in patients with FAP, and data pooled from 5 European polyposis registries found that only 0.2% of patients developed cancer before the age of 15 years and 1.3% developed cancer before the age of 20 years.[32–35]

Screening strategies rely on 2 features of FAP. The first is that the rectum is almost always affected in classic FAP and the second is that the progression from polyp to cancer is not accelerated despite polyp formation at a young age.[36] Predictive genetic testing should be offered to at-risk children at the age of 12 to 14 years. Children confirmed to have FAP on predictive genetic testing and those considered at risk, in whom genetic testing is not possible, should have surveillance colonoscopy starting at the age of 12 to 14 years. If the child is symptomatic with rectal bleeding or mucous discharge, a colonoscopy should be considered at any age.[37] There are limited data to guide decision-making for children of affected individuals who reach adulthood without a phenotype of polyposis and without a genetic diagnosis. It is, however, reasonable for colonoscopy to be repeated every 2 years until the age of 20 years.[38] In the absence of adenomas, surveillance intervals can be gradually extended for these patients.

Surgical Treatment of FAP

4. Total abdominal colectomy with ileorectal anastomosis (TAC-IRA) can be offered to FAP patients with relative rectal sparing if all rectal adenomas of >5 mm size can be endoscopically removed. Proctocolectomy with ileostomy or IPAA is the treatment of choice for patients with a rectal adenoma that cannot be managed endoscopically. Strength of recommendation: conditional based on low-quality evidence.

The goal of surgery in patients with FAP is to prevent cancer development while maximizing quality of life. In general, due to their polyp burden, attempting colonoscopic clearance of adenomas in patients with FAP does not adequately prevent cancer, necessitating prophylactic surgical resection of the at-risk mucosa. Multiple factors need to be considered when determining the timing of surgery, extent of resection, and operative plan. Polyp size and number can guide the timing of surgical intervention in children and young adults with FAP.[39] A retrospective study of 79 patients with FAP demonstrated that surgery can safely be postponed for months to years in patients with polyps <5 mm in size so long as serial endoscopic surveillance does not demonstrate progression of polyposis.[40]

The surgical options to treat FAP typically include TAC-IRA, proctocolectomy with stapled IPAA, proctocolectomy with mucosectomy and handsewn IPAA, and total proctocolectomy with end ileostomy. Although there is no randomized trial comparing IRA to proctocolectomy with IPAA, a meta-analysis of 12 nonrandomized studies including 1002 patients demonstrated better functional outcomes in patients with IRA but a 5% to 6% chance

Copyright © The American Society of Colon & Rectal Surgeons, Inc. Unauthorized reproduction of this article is prohibited.

of development of rectal cancer. Thus, an individualized approach is recommended.[41,42] Before restorative proctocolectomy with IPAA was available, patients typically underwent TAC-IRA and accepted the risk of developing cancer in the retained rectum to avoid an ileostomy.[43] Because restorative proctocolectomy became widely available, the decision of whether to retain the rectum has been made on the basis of functional considerations and on polyposis phenotype (ie, the degree of rectal sparing).[1,31,32,43–45] Population-based data from 4 European centers evaluating 776 patients who underwent IRA (576 from the pre-IPAA era) found that the cumulative risk of rectal cancer was 10% in the pre-IPAA era versus 2% in the IPAA era.[33] In terms of rectal polyp burden influencing the risk of subsequent rectal cancer, a cohort study of 213 patients with FAP found that the incidence of rectal cancer was 1.6% in patients with fewer than 20 rectal polyps (n = 128) compared to 10.8% in patients with more than 20 rectal polyps (n = 37).[46] A cohort study from the Singapore Polyposis Registry examined 122 patients with FAP from 88 families over 20 years and reported that cancer recurrence and disease-free survival was not different with selective use of IRA (relative paucity of rectal polyps during original operation) after 98 months of follow-up.[47] In addition, a recent study suggested a low rate of secondary proctectomy after IRA.[48] The authors analyzed 234 patients who underwent IRA between 1993 and 2015; with a median follow-up of 171 months, 6.1% of the patients subsequently underwent proctectomy, of whom 2.5% had rectal cancer. Endoscopic surveillance for polyps or malignancy in the retained rectum is typically recommended annually but can be extended to every 2 years based on polyp burden.[49] Surveillance and polypectomy of the rectum, ileoanal pouch, or rectal cuff may delay or decrease the need for further surgery to clear polyps.

Factors that support a proctectomy include having rectal cancer, a significant rectal polyp burden (more than 20 synchronous adenomas, adenomas with high-grade dysplasia, large [>30 mm] adenomas), a severe family history of aggressive phenotype (more than 1000 synchronous adenomas), and the desire for the highest degree of cancer risk reduction. Proctocolectomy with IPAA harbors a very small risk of developing future adenocarcinoma. A small number of cases have been reported in the literature, and most occurred in the retained rectum or in the anal transition zone (ATZ) mucosa.[50–54] A recent meta-analysis comparing patients undergoing IPAA for FAP compared to ulcerative colitis showed a 0.01% chance of cancer in the body of the pouch in FAP compared to 0.003% in UC.[55]

Whether a mucosectomy of the ATZ should be performed in the setting of surgery for FAP has been debated over the years. Mucosectomy with handsewn IPAA may result in worse functional outcomes compared with a stapled IPAA.[32] The risk of having future adenomas after mucosectomy is lower than after stapled IPAA (10% vs 31% at 7 years and 22% vs 51% at 10 years, respectively)[56,57]; there is no significant difference in cancer incidence between the 2 operative approaches.[57] Overall, although the quality of evidence is low, the available data do not support routine mucosectomy. Annual endoscopic surveillance of the remaining rectal and ATZ mucosa and of the ileal pouch is recommended to detect adenomas/dysplasia. Although the overall prevalence of pouch neoplasia is estimated to be around only 0.01%, it is the leading cause of pouch excision in patients with FAP.[54,55,58,59] Mucosectomy should be performed if the polyp burden extends to the dentate line or the ATZ cannot be cleared to the point at which adenomas would be included in the anastomosis.

Total proctocolectomy with end ileostomy can be considered for patients with poor sphincter function, distal rectal cancer, cancer requiring radiotherapy, or the desire to avoid the functional sequelae of an ileoanal pouch. Pelvic external beam radiation therapy before the creation of an IPAA can lead to worse short and long-term functional outcomes, including leakage and incontinence, but is not considered an absolute contraindication to pouch surgery.[60] In addition, because of the high risk of developing subsequent rectal cancer, it is important to offer IRA as a shared decision-making option for patients who will be compliant with endoscopic follow-up. Some patients have limited ability to follow-up because of social, financial, or mental health concerns.

Extracolonic Manifestations of FAP

5. Screening for duodenal adenomas in patients with FAP should begin with a baseline esophagogastroduodenoscopy (EGD) at the age of 20 to 25 years, and subsequent examinations should be performed at intervals based on endoscopic findings. Strength of recommendation: strong based on low-quality evidence.

Although we recommend screening the duodenum because of increased incidence of polyps and cancer, the complete management of duodenal neoplasia in this setting needs to be individualized and should involve multidisciplinary collaboration with an advanced endoscopist and a hepatobiliary surgeon. The nuances of this management are beyond the scope of this guideline. Three prospective studies and multiple retrospective studies support screening patient with adenomatous polyposis to detect duodenal polyposis.[61–64] In a prospective multinational European study that screened 368 FAP patients with biannual upper endoscopy, the cumulative incidence of duodenal adenoma and cancer by the age of 70 years was 90% and 4.5%, respectively.[61] Although these incidences are 100 to 300 times higher than the incidence of duodenal neoplasia in the general population, the low absolute cancer incidence and the prolonged time interval for transformation from adenoma to

Copyright © The American Society of Colon & Rectal Surgeons, Inc. Unauthorized reproduction of this article is prohibited.

TABLE 3. Spigelman classification for duodenal polyps in FAP

	Points		
Criteria	*1*	*2*	*3*
Polyp size, mm	1–4	5–10	>10
Polyp number	1–4	5–20	>20
Histology	Tubular	Tubulovillous	Villous
Dysplasia	Mild	Moderate	Severe

Spigelman stage—stage 0: 0 points; stage I: 1–4 points; stage II: 5–6 points; stage III: 7–8 points; stage IV: 9–12 points.
FAP = familial adenomatous polyposis.

carcinoma make it difficult to design a study that would show a reduction in duodenal cancer incidence based on endoscopic screening. Duodenal cancer in the setting of FAP is rare before the age of 30 years and, in the absence of symptoms, screening can begin at the age of 20 to 25 years. The Spigelman classification stratifies the risk of developing duodenal cancer based on polyp number, size, and histology and the degree of dysplasia[65] (Table 3). In a cohort of 114 patients with FAP who were prospectively followed for a median of 10 years, 6 of 114 patients (5.2%) developed cancer, and of the 11 patients with the most advanced polyps (ie, Spigelman IV), 4 (38%) developed cancer. These data suggest that endoscopic management may be appropriate for Spigelman I to III disease and that pancreas-preserving duodenectomy should be considered for patients with Spigelman IV disease.[66] A prospective cohort of patients with FAP in an endoscopic surveillance program in Toronto showed that, with a prospectively defined endoscopic management strategy, progression to cancer was slow, averaging 15 years after the initial endoscopy, and occurred in only 5 of 167 patients (3%).[67] The optimal age to start screening is based on consensus opinion and intervals for endoscopy should be based on the findings of prior upper GI EGD. In general, EGD is recommended every 5 years after a normal examination, every 2 to 3 years for Spigelman I, every 1 to 2 years for Spigelman stage II, and every 6 to 12 months for Spigelman stage III.[63] Spigelman stage IV patients should be managed by a multidisciplinary team with individualized decision-making regarding ongoing endoscopic surveillance versus surgical resection. If a patient does have a pancreaticoduodenectomy, it is reasonable to continue gastric surveillance because of the risk of gastric polyps detailed in the following paragraphs.

Gastric adenoma and cancer are not prominent extracolonic manifestations of FAP in the Western world, with an incidence of 2% to 10% and 1%, respectively.[68] The risk increases significantly, almost 7- to 10-fold, in Asian FAP populations. Gastric polyps are commonly noted on surveillance endoscopy for duodenal polyposis, with fundic gland polyps being the most commonly observed lesions.[69] Data from the polyposis registry of the International Society of Gastrointestinal Hereditary tumors group of 1435 patients with FAP between 1974 and 2015 described that 8 cases of gastric cancer occurred at a younger age, presented with subtle signs or were asymptomatic, and had a dismal prognosis because of the frequent presentation with metastatic disease.[69] Despite endoscopic surveillance, most patients presented with advanced tumors at diagnosis.[70] Another study reporting on upper digestive lesions in 140 patients with FAP from 1958 to 2017 found 5 gastric adenomas (2 advanced lesions) and 4 gastric cancers, which prompted the authors to recommend long-term endoscopic surveillance.[71] In contrast to these findings, a study from a large tumor registry identified a significant increase in cases of gastric adenocarcinoma. No cases were diagnosed from 1979 to 2006. However, 9 cases of gastric cancer arose between 2012 and 2016. Importantly, all of these developed in the setting of yearly endoscopic surveillance. All cases arose in the setting of carpeting of fundic gland polyposis and polypoid masses of gastric polyps in the proximal stomach.[69]

Adrenal masses are also found more frequently in patients with FAP. Evidence suggests that 7% of patients with FAP or its variants have adrenal masses, compared to 3% in the general public.[72–74] Importantly, these masses are typically nonfunctional and have not been shown to have more malignant potential than those found in the general population. Thus, they should be managed similarly to adrenal masses found in the general population.

6. Patients with FAP are at increased risk of thyroid cancer and may undergo thyroid cancer screening with annual physical examination and ultrasound starting in the late teens. Strength of recommendation: conditional based on very low–quality evidence.

Thyroid cancer occurs in 1% to 2% of patients with FAP compared with an incidence of 0.2% in the general population.[75–78] There are no prospective studies evaluating thyroid screening strategies with physical examination and ultrasound in the setting of FAP. A retrospective study of 192 patients with FAP who underwent universal screening (for all and any possible associated neoplasms) found that 72 patients (38%) had a thyroid nodule and 5 patients (2.6%) had thyroid cancer.[79] In another screening study of 50 patients with FAP who underwent ultrasound investigation, 7 patients (14%) had a subsequent fine-needle aspiration and 2 (4%) were found to have a papillary thyroid cancer.[80] A subsequent retrospective study compared patients with screening-detected cancers versus incident cancers and reported that screening-detected smaller tumors with fewer positive lymph nodes.[81] Although thyroid screening programs in patients with FAP have reported increased identification of thyroid cancers, it is unclear whether screening decreases all-cause mortality. In 2018, a study using the Dutch polyposis registry reported 85 extracolonic malignancies in 74 of 582 patients with known APC pathogenic variants.[64] In this study, thyroid cancer was observed in 1.5% of patients with FAP and accounted for only 1 cancer-related death. Cancer was the main cause of mortality in this cohort, accounting for 59% of all deaths; of these,

Copyright © The American Society of Colon & Rectal Surgeons, Inc. Unauthorized reproduction of this article is prohibited.

colorectal cancer accounted for 42% of deaths and duodenal cancer for 21%, thereby prompting the authors to suggest that cancer screening outside the GI tract may have limited benefit with regard to overall survival.

MYH-Associated Polyposis

7. Patients with biallelic *MUTYH* pathogenic variants should typically undergo yearly colonoscopy if the adenoma burden can be cleared endoscopically. First-degree relatives of an affected patient are recommended to undergo genetic counseling and testing for *MUTYH*. Strength of recommendation: conditional based on low-quality evidence.

In general, the colorectal MAP phenotype resembles that of attenuated FAP, but individuals with biallelic pathogenic variants may present with an apparently sporadic cancer or cancer at a young age. The average age of colorectal cancer in patients with MAP is 47 (range, 29–72) years.[82–85] Colorectal cancer due to biallelic *MUTYH* pathogenic variants before the age of 30 years is rare, and because of lower polyp numbers, maintaining endoscopic clearance of polyps is possible in some patients. Rectal cancer is relatively uncommon in MAP.[86,87] A study of 23 patients with MAP from 21 families with a median follow-up of 10 years found that 53% of polyps were distributed in the right colon, 40% in the left colon and 7% in the rectum.[88] A population-based study of 9268 patients with colorectal cancer identified 27 patients with biallelic *MUTYH* pathogenic variants who had more proximal cancers compared to sporadic cases (noncarriers).[85] A registry-based cohort study from the Netherlands demonstrated that 62% of MAP-associated cancers occurred proximal to the splenic flexure.[89] A retrospective review from the National Cancer Institute of Milan evaluated 130 patients with MAP from 98 families and found that 63.8% were symptomatic at the time of cancer diagnosis.[90] In this study, 75 patients (57.7%) presented with cancer at diagnosis and 59 patients (78.7%) presented with less than 100 adenomas. Left-sided colorectal cancer, contrary to previous reports, was more prevalent and found in 55.3% of this cohort. Siblings of a proband who have not yet had genetic testing are typically recommended to have a colonoscopy every other year starting at the age of 18 to 20 years.[2,20,89] Flexible sigmoidoscopy under these circumstances is not acceptable for screening because of the frequency of proximal colon cancer.

8. The timing and extent of resection recommended for patients with biallelic *MUTYH* pathogenic variants depends on the ability to clear polyps, the rectal polyp burden, and the presence of malignancy. Strength of recommendation: conditional based on very low–quality evidence.

Biallelic *MUTYH* pathogenic variants confer an increased risk of colorectal cancer with high penetrance by the age of 60 years. Thirty to 40% of adenomatous polyposis cases in which an *APC* pathogenic variant is not found may be because of biallelic *MUTYH* pathogenic variants.[91] There are also reported cases of colorectal cancer associated with these variants but without polyposis.[91,92] Because of the variation in presenting phenotype, insufficient data support a universal management approach. Several factors can influence the decision for surgery in this setting, including anticipated patient compliance with endoscopic surveillance, comorbidities, and the presence of cancer. TAC-IRA may be preferred in situations in which there is relatively mild rectal polyposis (less than 20 polyps) and small polyps (<9 mm) and there is a priority to preserve fertility.[93,94] Age of primary surgery may also play a role. In a series of 427 patients who underwent IRA and with a median follow-up of 15 years, 11.2% developed rectal cancer and 18% needed proctectomy for worsening polyposis. Patients with IRA before the age of 25 years were twice as likely to need proctectomy over time.[95] If an IRA is performed, long-term endoscopic surveillance of the retained rectum annually and then every 2 years is recommended, although it is driven in large part by expert opinion.[4,96]

Extracolonic Manifestations of MAP

9. In patients with MAP, upper endoscopy is recommended beginning at the age of 30 years, with subsequent examinations at intervals based on the endoscopic findings. Strength of recommendation: conditional based on very low–quality evidence.

Extracolonic manifestations of MAP include duodenal cancers and extraintestinal neoplasia such as osteomas, dental cysts, and sebaceous gland tumors. It is important for complete viewing of the ampullary region because periampullary polyps commonly occur in these patients. Data regarding the risk for upper GI malignancies are less robust compared to FAP and reported rates of duodenal neoplasia ranging from 17% to 34%.[97,98] A multicenter registry-based cohort of European centers, including 276 patients from 181 families, reported a 17% prevalence of duodenal polyps and a 4% lifetime risk of duodenal cancer.[98] The frequency of duodenal adenomas in patients with MAP is much lower than that observed in FAP but greater than in the general population. The American College of Gastroenterology and the Association of Coloproctology of Great Britain and Ireland recommend screening with EGD starting at the age of 25 to 35 years.[2,4] The interval between surveillance examinations depends on the number of duodenal adenomas and adenoma characteristics, including size, histology, and the degree of dysplasia.[65] Patients may be managed with the aid of the Spigelman criteria with the caveat that these are extrapolated from the FAP literature and were not developed specifically for MAP patients. Although there may be an increased incidence of ovarian, bladder, and skin cancer, insufficient data are available to support specific screening

Copyright © The American Society of Colon & Rectal Surgeons, Inc. Unauthorized reproduction of this article is prohibited.

recommendations for these extraintestinal malignancies in the setting of MAP.[4]

Chemoprevention of Adenomas

10. Patients with FAP or MAP with retained colon or rectum may be considered for chemoprevention for adenomas. Strength of recommendation: conditional based on high-quality evidence.

Chemoprevention with nonsteroidal medications, such as sulindac or celecoxib, induces temporary polyp regression in FAP through a variety of potential mechanisms, such as increasing prostaglandin levels, reducing epithelial COX-2 expression, and inducing *K-ras* pathogenic variants and alterations in stem cell behavior.[99] Importantly, no drug is approved by the Food and Drug Administration for the indication of chemoprevention in the setting of polyposis despite more than a dozen randomized controlled and observational trials evaluating chemoprevention in this setting.[100–114] Of 5 RCTs examining the use of sulindac, 4 reported a significant reduction in the polyp burden.[100–103,115] The single negative trial was a primary prevention trial in patients who were phenotypically unaffected but who had an *APC* pathogenic variant; these findings may not be representative of the population of postoperative patients with a highly penetrant polyposis phenotype.[103]

One randomized trial evaluating dual treatment with sulindac and erlotinib (tyrosine kinase inhibitor approved for pancreatic and non–small cell lung cancer) for duodenal polyp suppression in patients with FAP was stopped early because of the demonstrated superiority of the chemoprevention over placebo (decrease in median polyp number −8 and in size −19 mm in treatment group compared to placebo), although there was a high rate of grade 1 and 2 adverse events in the study arm, including an acne-like rash in 87% of treated patients.[104] A prespecified secondary analysis of the trial assessed colorectal adenoma formation and regression. Of the 82 patients (41 placebo and 41 sulindac/erlotinib), the total colorectal polyp count was significantly decreased in the treatment group at 6 months with a net percentage change of 69.4% (95% CI, 28.8%–109.2%; $p = 0.009$).[116] Of the 7 randomized trials examining the role of selective cyclooxygenase-2 inhibitors on rates of duodenal polyp burden, 6 reported positive results.[105–110,117] An international RCT of celecoxib and difluoromethylornithine (primarily approved for sleeping sickness) showed that the addition of difluoromethylornithine was required to achieve a 40% decrease in adenoma burden compared to 27% with placebo.[117] Another randomized trial analyzed eicosapentaenoic acid (an omega-3 fatty acid) with positive results.[117] Three randomized studies have analyzed vitamin C, vitamin E, calcium, or a combination of these and reported mixed but overall negative results.[112–114] It is important to distinguish that all of the above-mentioned trials were designed to detect differences in adenoma burden, but the clinically important outcome of cancer risk has not been directly investigated.

Desmoid Disease

Desmoid tumors are locally aggressive, mesenchymal monoclonal proliferations that lack metastatic potential. Approximately 10% to 15% of desmoids are FAP associated, and these tumors frequently develop after surgical trauma (up to 72% after colectomy for FAP) and most commonly occur intra-abdominally or within the abdominal wall.[118,119] The clinical course of a desmoid tumor can range from a stable disease requiring no intervention to rapid growth resulting in tumor-related complications to spontaneous regression. Compared to sporadic desmoids, FAP-associated tumors present at a younger age and are a significant cause of death among patients with FAP (implicated in 21% of deaths).[119,120] In patients with desmoids, *CTNNB1* pathogenic variants and *APC* pathogenic variants are mutually exclusive; thus, detection of a somatic *CTNNB1* pathogenic variant helps exclude a diagnosis of FAP. Meanwhile, *CTNNB1* wild-type status in a patient with a desmoid tumor, especially when located intra-abdominally, should raise suspicion for FAP and prompt a more extensive diagnostic work-up.[118,121,122]

Because desmoids tend to be rare, there is no high-quality evidence to suggest a management strategy particularly when the disease location is in the abdominal wall. An international panel of experts, "The Desmoid Tumor Working Group," recommended the management of asymptomatic patients with abdominal wall desmoid disease to an initial strategy of observation. The group concluded that "surgery may still be considered as a second-line treatment for abdominal wall desmoid disease." It is difficult to make clear recommendations on this topic because the data are limited to very low-quality evidence. For further reading on desmoid disease, please refer to the consensus document directly.[121]

11. Pharmacologic treatment, rather than surgery, is the preferred initial approach for patients with polyposis-associated intra-abdominal desmoid disease. Strength of recommendation: strong based on moderate-quality evidence.

Whether to survey patients with clinically and radiographically stable or regressing desmoid disease, versus actively using a pharmacologic treatment approach, has not been well studied. In addition, the literature is lacking with regard to comparing different treatment approaches between antihormonal therapies, nonsteroidal anti-inflammatory drugs, tyrosine kinase inhibitors, and "low-dose" or conventional chemotherapeutic regimens. Although retrospective series have reported potential benefits of antihormonal therapy and/or nonsteroidal

Copyright © The American Society of Colon & Rectal Surgeons, Inc. Unauthorized reproduction of this article is prohibited.

anti-inflammatory drugs in the setting of polyposis-related desmoids, the only prospective phase II study evaluating antihormonal therapy plus sulindac showed limited efficacy.[123] Meanwhile, the tyrosine kinase inhibitor imatinib has shown activity and disease stabilization (60%–80%) in 3 prospective phase II studies.[124–126] However, given the recognized phenomenon of spontaneous desmoid regression, these nonrandomized studies make it difficult to confidently define the role of imatinib in this setting. A phase III placebo-controlled randomized trial evaluating sorafenib, the best-studied tyrosine kinase inhibitor agent for desmoids, reported a 7-fold reduction in the risk of desmoid progression and a response rate of 33% in the treatment group (n = 49) versus 20% in the placebo group (n = 36).[127] Progression-free survival at 2 years was 81% in the treatment group compared to 36% in the placebo group. The randomized controlled trial of nirogacestat (γ-secretase inhibitor) showed significant improvement in symptoms and decreased tumor measurements at 2 years (41% vs 8%, $p < 0.001$).[128] These results are of questionable utility because not all of the patients studied had FAP. Meanwhile, chemotherapy regimens, including methotrexate plus vinblastine and anthracycline-based combinations, have demonstrated response rates of 30% to 40% in both retrospective and prospective phase II studies.[129–131]

12. Surgery for intra-abdominal desmoid tumors should typically be reserved for symptomatic patients not responsive to medical therapy. Grade of recommendation: conditional based on low-quality evidence.

Historically, en bloc resection of desmoids in both symptomatic and asymptomatic patients was the cornerstone of treatment. However, given the risk of substantial surgical morbidity, high recurrence rates after resection, and unpredictable biology, surveillance is the currently recommended primary management rather than medical or surgical intervention.[121] For enlarging FAP-associated desmoid tumors located in critical anatomic sites (eg, root of the mesentery) or causing tumor-related complications (eg, obstruction, fistulization, pain), multidisciplinary treatment should be considered, consisting of systemic therapies, radiation, and/or operative intervention.

Surveillance in the setting of FAP-related desmoids typically involves interval cross-sectional imaging obtained at 3- to 6-month intervals. Optimal imaging frequency is individualized, however, and depends on the anatomic location of the tumor, the risk of progression, and the presence of symptoms related to progression.[20,132] Regular interval imaging surveillance is recommended for 2 to 3 years from the time of desmoid diagnosis, after which intervals may be extended to 6 to 12 months if clinically and radiographically appropriate.[20]

Multiple single-center retrospective reports have attempted to define the role of surgery in this setting, but the heterogeneity of patients, lack of standardization, and unavoidable treatment bias limit the generalizability of results. A large single-institution retrospective series of 495 patients who underwent desmoid resection (only 4% were FAP-associated) identified young age (younger than 25 years), large tumor size (>10 cm), and intra-abdominal location (rather than abdominal wall) as risk factors for recurrence.[133] Results from a national French database comparing initial surgery to surveillance showed no difference in event-free survival (53% vs 58%; $p = 0.41$) as related to desmoid tumors.[134] Similarly, a Dutch retrospective study examining a FAP registry reported comparable long-term progression-free survival rates among 78 patients with FAP-associated desmoid regardless of a surgical or nonsurgical management approach, with 77% of patients displaying regression or stability during a median follow-up of 8 years.[135] In the placebo group of the aforementioned sorafenib prospective study, 20% of patients in the placebo group showed no objective growth.[127] Given the available data, first-line treatment for most patients with desmoids should typically focus on surveillance.[132] Although an initial surveillance strategy may result in up to 40% of patients experiencing disease progression or requiring a change in therapeutic strategy, deferring upfront resection likely avoids overtreating desmoids that may spontaneously regress, remain stable, or cause minimal symptoms. Surgery may be a reasonable initial treatment approach for extra-abdominal or abdominal wall desmoid tumors unless major surgical morbidity is anticipated and remains the primary approach to intra-abdominal desmoids resulting in hollow viscus perforation, obstruction, or fistulization.

Before proceeding with colectomy in the setting of FAP, it is important to consider the potential impact of the operative approach on future desmoid tumor formation. Retrospective series indicate that a minimally invasive approach with IRA, compared to a restorative proctocolectomy, is associated with a lower risk of future desmoid formation.[136–139] However, conflicting reports suggest that the operative approach and extent of operation result in a similar risk for desmoid formation.[140–143] Based on the body of retrospective literature with its inherent selection bias, the risk of desmoid tumors after surgical trauma remains unclear and, likely, multifactorial. Other factors, such as *APC* genotype, family history, and sex, rather than surgical trauma alone, may influence desmoid formation in patients with FAP.[144]

Surveillance and Treatment of Polyposis Without an Identified Pathogenic Variant

13. Patients with clinical polyposis, but without an identified pathogenic variant, should be managed on the basis of their phenotype. Strength of recommendation: conditional based on very low–quality evidence.

Between 20% and 50% of patients with attenuated polyposis will not have a variant found in the *APC* or *MYH* genes.[10,145,146] Multiple case series have described alterations

Copyright © The American Society of Colon & Rectal Surgeons, Inc. Unauthorized reproduction of this article is prohibited.

that are not included in existing commercial testing that may play a role in polyposis, such as genomic rearrangements involving *APC*, *APC* mosaicism, and pathogenic variants in the *APC* promoter.[147–149] Other patients may harbor rare or as yet unknown causes of polyposis, such as the more recently described polymerase proofreading-associated polyposis.[150]

Management of patients with polyposis without identifiable pathogenic variants has been described in observational studies. In a study of 27 "variant-negative" polyposis patients with an average of 51 polyps, 67% of patients underwent colectomy after a mean of 3.1 years after diagnosis because of the concern for cancer or inability to provide endoscopic clearance.[146] In this study, extracolonic findings mirrored attenuated polyposis syndromes, and 47% of patients had foregut polyps. In another observational study of 66 Italian patients with FAP, 32 cases of *APC* variant-negative polyposis were identified. These patients were less likely to display extracolonic manifestations.[151] In the absence of a known pathogenic variant, it is reasonable to treat patients according to their phenotype by maintaining endoscopic clearance in patients when possible and proceeding with colectomy or proctocolectomy if required because of polyp burden,[151] though these recommendations are based on limited observational data.[20]

REFERENCES

1. Herzig D, Hardiman K, Weiser M, et al. The American Society of Colon and Rectal Surgeons clinical practice guidelines for the management of inherited polyposis syndromes. *Dis Colon Rectum*. 2017;60:881–894.
2. Monahan KJ, Bradshaw N, Dolwani S, et al; Hereditary CRC guidelines eDelphi consensus group. Guidelines for the management of hereditary colorectal cancer from the British Society of Gastroenterology (BSG)/Association of Coloproctology of Great Britain and Ireland (ACPGBI)/United Kingdom Cancer Genetics Group (UKCGG). *Gut*. 2020;69:411–444.
3. Bussey HJ, Veale AM, Morson BC. Genetics of gastrointestinal polyposis. *Gastroenterology*. 1978;74:1325–1330.
4. Syngal S, Brand RE, Church JM, Giardiello FM, Hampel HL, Burt RW; American College of Gastroenterology. American College of Gastroenterology. ACG clinical guideline: genetic testing and management of hereditary gastrointestinal cancer syndromes. *Am J Gastroenterol*. 2015;110:223–62; quiz 263.
5. Kinzler KW, Nilbert MC, Su LK, et al. Identification of FAP locus genes from chromosome 5q21. *Science*. 1991;253:661–665.
6. Bisgaard ML, Fenger K, Bülow S, Niebuhr E, Mohr J. Familial adenomatous polyposis (FAP): frequency, penetrance, and mutation rate. *Hum Mutat*. 1994;3:121–125.
7. Zhu L, Li X, Yuan Y, Dong C, Yang M. APC promoter methylation in gastrointestinal cancer. *Front Oncol*. 2021;11:653222.
8. Half E, Bercovich D, Rozen P. Familial adenomatous polyposis. *Orphanet J Rare Dis*. 2009;4:22.
9. Heinen CD. Genotype to phenotype: analyzing the effects of inherited mutations in colorectal cancer families. *Mutat Res*. 2010;693:32–45.
10. Grover S, Kastrinos F, Steyerberg EW, et al. Prevalence and phenotypes of APC and MUTYH mutations in patients with multiple colorectal adenomas. *JAMA*. 2012;308:485–492.
11. Guyatt G, Oxman AD, Akl EA, et al. GRADE guidelines: 1. Introduction-GRADE evidence profiles and summary of findings tables. *J Clin Epidemiol*. 2011;64:383–394.
12. Bülow S, Faurschou Nielsen T, Bülow C, Bisgaard ML, Karlsen L, Moesgaard F. The incidence rate of familial adenomatous polyposis. Results from the Danish Polyposis Register. *Int J Colorectal Dis*. 1996;11:88–91.
13. Burt R, Neklason DW. Genetic testing for inherited colon cancer. *Gastroenterology*. 2005;128:1696–1716.
14. Scheuner MT, McNeel TS, Freedman AN. Population prevalence of familial cancer and common hereditary cancer syndromes. The 2005 California Health Interview Survey. *Genet Med*. 2010;12:726–735.
15. Gupta S, Provenzale D, Regenbogen SE, et al. NCCN Guidelines Insights: genetic/familial high-risk assessment: colorectal, version 3.2017. *J Natl Compr Canc Netw*. 2017;15:1465–1475.
16. Pearlman R, Frankel WL, Swanson B, et al; Ohio Colorectal Cancer Prevention Initiative Study Group. Prevalence and spectrum of germline cancer susceptibility gene mutations among patients with early-onset colorectal cancer. *JAMA Oncol*. 2017;3:464–471.
17. Stoffel EM, Koeppe E, Everett J, et al. Germline genetic features of young individuals with colorectal cancer. *Gastroenterology*. 2018;154:897–905.e1.
18. Yang J, Gurudu SR, Koptiuch C, et al. American Society for Gastrointestinal Endoscopy guideline on the role of endoscopy in familial adenomatous polyposis syndromes. *Gastrointest Endosc*. 2020;91:963–982.e2.
19. Boardman LA, Vilar E, You YN, Samadder J. AGA Clinical Practice Update on young adult-onset colorectal cancer diagnosis and management: expert review. *Clin Gastroenterol Hepatol*. 2020;18:2415–2424.
20. Weiss JM, Gupta S, Burke CA, et al. NCCN Guidelines® Insights: genetic/familial high-risk assessment: colorectal, version 1.2021. *J Natl Compr Canc Netw*. 2021;19:1122–1132.
21. Aretz S, Uhlhaas S, Caspari R, et al. Frequency and parental origin of de novo APC mutations in familial adenomatous polyposis. *Eur J Hum Genet*. 2004;12:52–58.
22. Murff HJ, Byrne D, Syngal S. Cancer risk assessment: quality and impact of the family history interview. *Am J Prev Med*. 2004;27:239–245.
23. Statement of the American Society of Clinical Oncology: genetic testing for cancer susceptibility, adopted on February 20, 1996. *J Clin Oncol*. 1996;14:1730–1736.
24. Geller G, Botkin JR, Green MJ, et al. Genetic testing for susceptibility to adult-onset cancer. The process and content of informed consent. *JAMA*. 1997;277:1467–1474.
25. Riley BD, Culver JO, Skrzynia C, et al. Essential elements of genetic cancer risk assessment, counseling, and testing: updated recommendations of the National Society of Genetic Counselors. *J Genet Couns*. 2012;21:151–161.
26. Del Fiol G, Kohlmann W, Bradshaw RL, et al. Standards-based clinical decision support platform to manage patients who meet guideline-based criteria for genetic evaluation of familial cancer. *JCO Clin Cancer Inform*. 2020;4:1–9.

Copyright © The American Society of Colon & Rectal Surgeons, Inc. Unauthorized reproduction of this article is prohibited.

27. Healy MA, Thirumurthi S, You YN. Screening high-risk populations for colon and rectal cancers. *J Surg Oncol*. 2019;120:858–863.
28. Barrow P, Khan M, Lalloo F, Evans DG, Hill J. Systematic review of the impact of registration and screening on colorectal cancer incidence and mortality in familial adenomatous polyposis and Lynch syndrome. *Br J Surg*. 2013;100:1719–1731.
29. Warrier SK, Kalady MF, Kiran RP, Church JM. Results from an American Society of Colon and Rectal Surgeons survey on the management of young-onset colorectal cancer. *Tech Coloproctol*. 2014;18:265–272.
30. Alexander JL, Johnston BJ, Smith TJ, et al. Low referral rates for genetic assessment of patients with multiple adenomas in United Kingdom bowel cancer screening programs. *Dis Colon Rectum*. 2021;64:1058–1063.
31. Stanich PP, Pearlman R, Hinton A, et al. Prevalence of germline mutations in polyposis and colorectal cancer-associated genes in patients with multiple colorectal polyps. *Clin Gastroenterol Hepatol*. 2019;17:2008–2015.e3.
32. Stoffel EM, Mangu PB, Limburg PJ; American Society of Clinical Oncology; European Society for Medical Oncology. Hereditary colorectal cancer syndromes: American Society of Clinical Oncology clinical practice guideline endorsement of the familial risk-colorectal cancer: European Society for Medical Oncology clinical practice guidelines. *J Oncol Pract*. 2015;11:e437–e441.
33. Ten YV, Tillyashakhov M, Islamov H, Ziyaev Y. The risk of malignization incidence in patients with polyps and polyposis of the colon and rectum. *Ann Oncol*. 2019;30:ix37.
34. Quintero E, Carrillo M, Leoz ML, et al; Oncology Group of the Asociación Española de Gastroenterología (AEG). Risk of advanced neoplasia in first-degree relatives with colorectal cancer: a large multicenter cross-sectional study. *PLoS Med*. 2016;13:e1002008.
35. Church JM, McGannon E, Burke C, Clark B. Teenagers with familial adenomatous polyposis: what is their risk for colorectal cancer? *Dis Colon Rectum*. 2002;45:887–889.
36. Muto T, Bussey HJ, Morson BC. The evolution of cancer of the colon and rectum. *Cancer*. 1975;36:2251–2270.
37. Hyer W, Cohen S, Attard T, et al. Management of familial adenomatous polyposis in children and adolescents: position paper from the ESPGHAN polyposis working group. *J Pediatr Gastroenterol Nutr*. 2019;68:428–441.
38. Gupta S, Provenzale D, Llor X, et al; CGC. NCCN guidelines insights: genetic/familial high-risk assessment: colorectal, version 2.2019. *J Natl Compr Canc Netw*. 2019;17:1032–1041.
39. Sarvepalli S, Burke C, Laguardia L, O'Malley M, Church J. Indications for colectomy and factors influencing time to colectomy in children and young adults with familial adenomatous polyposis (FAP). *Fam Cancer*. 2017;16:S41.
40. Vasen HFA, Ghorbanoghli Z, de Ruijter B, et al. Optimizing the timing of colorectal surgery in patients with familial adenomatous polyposis in clinical practice. *Scand J Gastroenterol*. 2019;54:733–739.
41. Aziz O, Athanasiou T, Fazio VW, et al. Meta-analysis of observational studies of ileorectal versus ileal pouch-anal anastomosis for familial adenomatous polyposis. *Br J Surg*. 2006;93:407–417.
42. Anele C, Xiang J, Hawkins M, et al. Polyp progression in paediatric patients with familial adenomatous polyposis syndrome—a single center experience. *Colorectal Dis*. 2019;21:13.
43. Church J, Burke C, McGannon E, Pastean O, Clark B. Risk of rectal cancer in patients after colectomy and ileorectal anastomosis for familial adenomatous polyposis: a function of available surgical options. *Dis Colon Rectum*. 2003;46:1175–1181.
44. Bülow S, Bülow C, Vasen H, Järvinen H, Björk J, Christensen IJ. Colectomy and ileorectal anastomosis is still an option for selected patients with familial adenomatous polyposis. *Dis Colon Rectum*. 2008;51:1318–1323.
45. Siegel RL, Miller KD, Fuchs HE, Jemal A. Cancer statistics, 2021. *CA Cancer J Clin*. 2021;71:7–33.
46. Church J, Burke C, McGannon E, Pastean O, Clark B. Predicting polyposis severity by proctoscopy: how reliable is it? *Dis Colon Rectum*. 2001;44:1249–1254.
47. Chew MH, Quah HM, Teh KL, Loi TT, Eu KW, Tang CL. Twenty years of familial adenomatosis polyposis syndromes in the Singapore Polyposis Registry: an analysis of outcomes. *Singapore Med J*. 2011;52:246–251.
48. Liska D, Abbas MA, Burke C, et al. Risk of proctectomy after ileorectal anastomosis in familial adenomatous polyposis in the modern era. *Fam Cancer*. 2019;18:S61.
49. van Leerdam ME, Roos VH, van Hooft JE, et al. Endoscopic management of polyposis syndromes: European Society of Gastrointestinal Endoscopy (ESGE) guideline. *Endoscopy*. 2019;51:877–895.
50. Tajika M, Tanaka T, Ishihara M, et al. Long-term outcomes of metachronous neoplasms in the ileal pouch and rectum after surgical treatment in patients with familial adenomatous polyposis. *Endosc Int Open*. 2019;7:E691–E698.
51. Tajika M, Niwa Y, Bhatia V, Tanaka T, Ishihara M, Yamao K. Risk of ileal pouch neoplasms in patients with familial adenomatous polyposis. *World J Gastroenterol*. 2013;19:6774–6783.
52. Smith JC, Schäffer MW, Ballard BR, et al. Adenocarcinomas after prophylactic surgery for familial adenomatous polyposis. *J Cancer Ther*. 2013;4:260–270.
53. Boostrom SY, Mathis KL, Pendlimari R, Cima RR, Larson DW, Dozois EJ. Risk of neoplastic change in ileal pouches in familial adenomatous polyposis. *J Gastrointest Surg*. 2013;17:1804–1808.
54. Sriranganathan D, Vinci D, Pellino G, Segal JP. Ileoanal pouch cancers in ulcerative colitis and familial adenomatous polyposis: a systematic review and meta-analysis. *Dig Liver Dis*. 2022;54:1328–1334.
55. Sriranganathan D, Kilic Y, Nabil Quraishi M, Segal JP. Prevalence of pouchitis in both ulcerative colitis and familial adenomatous polyposis: a systematic review and meta-analysis. *Colorectal Dis*. 2022;24:27–39.
56. van Duijvendijk P, Vasen HF, Bertario L, et al. Cumulative risk of developing polyps or malignancy at the ileal pouch-anal anastomosis in patients with familial adenomatous polyposis. *J Gastrointest Surg*. 1999;3:325–330.
57. von Roon AC, Will OC, Man RF, et al. Mucosectomy with handsewn anastomosis reduces the risk of adenoma formation in the anorectal segment after restorative proctocolectomy for familial adenomatous polyposis. *Ann Surg*. 2011;253:314–317.
58. Patel S, Ahnen D, Gumidyala A, Lowery J, Cockburn M, Austin GL. Poor knowledge of personal and familial cancer risk and guideline-based screening recommendations in patients with advanced colorectal polyps [abstract Sa1003]. *Gastroenterology*. 2019;156:S–250.

Copyright © The American Society of Colon & Rectal Surgeons, Inc. Unauthorized reproduction of this article is prohibited.

59. Lattenist R, Léonard D, Bachmann R, et al. Total proctocolectomy with ileal pouch-anal anastomosis in the management of familial adenomatous polyposis and ulcerative colitis: relevance of endoanal mucosectomy and long-term functional outcomes. *Louv Med*. 2016;135:399–400.
60. Lightner AL, Spinelli A, McKenna NP, Warusavitarne J, Fleshner P. Does radiation to the pelvis portent worse ileal pouch outcomes? An international multi-institution collaborative study [abstract 859]. *Gastroenterology*. 2018;154:S–1290.
61. Bülow S, Alm T, Fausa O, Hultcrantz R, Järvinen H, Vasen H; DAF Project Group. Duodenal adenomatosis in familial adenomatous polyposis. *Int J Colorectal Dis*. 1995;10:43–46.
62. Cordero-Fernández C, Garzón-Benavides M, Pizarro-Moreno A, et al. Gastroduodenal involvement in patients with familial adenomatous polyposis. Prospective study of the nature and evolution of polyps: evaluation of the treatment and surveillance methods applied. *Eur J Gastroenterol Hepatol*. 2009;21:1161–1167.
63. Saurin JC, Gutknecht C, Napoleon B, et al. Surveillance of duodenal adenomas in familial adenomatous polyposis reveals high cumulative risk of advanced disease. *J Clin Oncol*. 2004;22:493–498.
64. Ghorbanoghli Z, Bastiaansen BAJ, Langers AMJ, et al. Extracolonic cancer risk in Dutch patients with APC (adenomatous polyposis coli)-associated polyposis. *J Med Genet*. 2018;55:11–14.
65. Spigelman AD, Williams CB, Talbot IC, Domizio P, Phillips RK. Upper gastrointestinal cancer in patients with familial adenomatous polyposis. *Lancet*. 1989;2:783–785.
66. Groves CJ, Saunders BP, Spigelman AD, Phillips RK. Duodenal cancer in patients with familial adenomatous polyposis (FAP): results of a 10 year prospective study. *Gut*. 2002;50:636–641.
67. Serrano PE, Grant RC, Berk TC, et al. Progression and management of duodenal neoplasia in familial adenomatous polyposis: a cohort study. *Ann Surg*. 2015;261:1138–1144.
68. Jawale R, Mankaney G, Leone P, et al. Recent increase in gastric carcinoma and characterization of gastric polyp burden in western patients with FAP. *Lab Invest*. 2017;97:177A.
69. Mankaney G, Leone P, Cruise M, et al. Gastric cancer in FAP: a concerning rise in incidence. *Fam Cancer*. 2017;16:371–376.
70. Walton SJ, Frayling IM, Clark SK, Latchford A. Gastric tumours in FAP. *Fam Cancer*. 2017;16:363–369.
71. Campos FG, Martinez CAR, Sulbaran M, Bustamante-Lopez LA, Safatle-Ribeiro AV. Upper gastrointestinal neoplasia in familial adenomatous polyposis: prevalence, endoscopic features and management. *J Gastrointest Oncol*. 2019;10:734–744.
72. Groen EJ, Roos A, Muntinghe FL, et al. Extra-intestinal manifestations of familial adenomatous polyposis. *Ann Surg Oncol*. 2008;15:2439–2450.
73. Smith TG, Clark SK, Katz DE, Reznek RH, Phillips RK. Adrenal masses are associated with familial adenomatous polyposis. *Dis Colon Rectum*. 2000;43:1739–1742.
74. Will OC, Hansmann A, Phillips RK, et al. Adrenal incidentaloma in familial adenomatous polyposis: a long-term follow-up study and schema for management. *Dis Colon Rectum*. 2009;52:1637–1644.
75. Bülow C, Bülow S. Is screening for thyroid carcinoma indicated in familial adenomatous polyposis? The Leeds Castle Polyposis Group. *Int J Colorectal Dis*. 1997;12:240–242.
76. Bülow S, Holm NV, Mellemgaard A. Papillary thyroid carcinoma in Danish patients with familial adenomatous polyposis. *Int J Colorectal Dis*. 1988;3:29–31.
77. van der Linde K, Vasen HF, van Vliet AC. Occurrence of thyroid carcinoma in Dutch patients with familial adenomatous polyposis. An epidemiological study and report of new cases. *Eur J Gastroenterol Hepatol*. 1998;10:777–781.
78. Giardiello FM, Offerhaus GJ, Lee DH, et al. Increased risk of thyroid and pancreatic carcinoma in familial adenomatous polyposis. *Gut*. 1993;34:1394–1396.
79. Jarrar AM, Milas M, Mitchell J, et al. Screening for thyroid cancer in patients with familial adenomatous polyposis. *Ann Surg*. 2011;253:515–521.
80. Steinhagen E, Hui VW, Levy RA, et al. Results of a prospective thyroid ultrasound screening program in adenomatous polyposis patients. *Am J Surg*. 2014;208:764–769.
81. Feng X, Milas M, O'Malley M, et al. Characteristics of benign and malignant thyroid disease in familial adenomatous polyposis patients and recommendations for disease surveillance. *Thyroid*. 2015;25:325–332.
82. Leite JS, Isidro G, Martins M, et al. Is prophylactic colectomy indicated in patients with MYH-associated polyposis? *Colorectal Dis*. 2005;7:327–331.
83. Nieuwenhuis MH, Vogt S, Jones N, et al. Evidence for accelerated colorectal adenoma-carcinoma progression in MUTYH-associated polyposis? *Gut*. 2012;61:734–738.
84. Lipton L, Halford SE, Johnson V, et al. Carcinogenesis in MYH-associated polyposis follows a distinct genetic pathway. *Cancer Res*. 2003;63:7595–7599.
85. Lubbe SJ, Di Bernardo MC, Chandler IP, Houlston RS. Clinical implications of the colorectal cancer risk associated with MUTYH mutation. *J Clin Oncol*. 2009;27:3975–3980.
86. Nascimbeni R, Pucciarelli S, Di Lorenzo D, et al. Rectum-sparing surgery may be appropriate for biallelic MutYH-associated polyposis. *Dis Colon Rectum*. 2010;53:1670–1675.
87. Valanzano R, Ficari F, Curia MC, et al. Balance between endoscopic and genetic information in the choice of ileorectal anastomosis for familial adenomatous polyposis. *J Surg Oncol*. 2007;95:28–33.
88. La Guardia L, O'Malley M, Leach B, et al. A registry for hereditary colorectal cancer syndromes: a regional referral center; a national resource [abstract 55]. *Fam Cancer*. 2019;18:S51–S52.
89. Nielsen M, Franken PF, Reinards TH, et al. Multiplicity in polyp count and extracolonic manifestations in 40 Dutch patients with MYH associated polyposis coli (MAP). *J Med Genet*. 2005;42:e54.
90. Ricci MT, Moschitta M, Pensotti V, et al. Clinical and molecular characteristics in 130 patients with MUTYH-associated polyposis: results from an hereditary polyposis registry. *Fam Cancer*. 2017;16:S40.
91. Sereno M, Merino M, López-Gómez M, et al. MYH polyposis syndrome: clinical findings, genetics issues and management. *Clin Transl Oncol*. 2014;16:675–679.
92. Markkanen E, Dorn J, Hübscher U. MUTYH DNA glycosylase: the rationale for removing undamaged bases from the DNA. *Front Genet*. 2013;4:18.
93. Vogelsang HE. Prophylactic surgery and extended oncologic radicality in gastric and colorectal hereditary cancer syndromes. *Visc Med*. 2019;35:231–239.
94. Church JM. Controversies in the surgery of patients with familial adenomatous polyposis and Lynch syndrome. *Fam Cancer*. 2016;15:447–451.

Copyright © The American Society of Colon & Rectal Surgeons, Inc. Unauthorized reproduction of this article is prohibited.

95. Sinha A, Tekkis PP, Rashid S, Phillips RK, Clark SK. Risk factors for secondary proctectomy in patients with familial adenomatous polyposis. *Br J Surg*. 2010;97:1710–1715.
96. Liang J, Church JM. Rectal cancers in patients with familial adenomatous polyposis. *Fam Cancer*. 2013;12:749–754.
97. Walton SJ, Kallenberg FG, Clark SK, Dekker E, Latchford A. Frequency and features of duodenal adenomas in patients with MUTYH-associated polyposis. *Clin Gastroenterol Hepatol*. 2016;14:986–992.
98. Vogt S, Jones N, Christian D, et al. Expanded extracolonic tumor spectrum in MUTYH-associated polyposis. *Gastroenterology*. 2009;137:1976–85.e1.
99. Ma H, Brosens LAA, Elias SG, et al. Longitudinal analysis of colon crypt stem cell dynamics in sulindac treated familial adenomatous polyposis patients. *Sci Rep*. 2017;7:11972.
100. Giardiello FM, Hamilton SR, Krush AJ, et al. Treatment of colonic and rectal adenomas with sulindac in familial adenomatous polyposis. *N Engl J Med*. 1993;328:1313–1316.
101. Labayle D, Fischer D, Vielh P, et al. Sulindac causes regression of rectal polyps in familial adenomatous polyposis. *Gastroenterology*. 1991;101:635–639.
102. Nugent KP, Farmer KC, Spigelman AD, Williams CB, Phillips RK. Randomized controlled trial of the effect of sulindac on duodenal and rectal polyposis and cell proliferation in patients with familial adenomatous polyposis. *Br J Surg*. 1993;80:1618–1619.
103. Giardiello FM, Yang VW, Hylind LM, et al. Primary chemoprevention of familial adenomatous polyposis with sulindac. *N Engl J Med*. 2002;346:1054–1059.
104. Samadder NJ, Neklason DW, Boucher KM, et al. Effect of sulindac and erlotinib vs placebo on duodenal neoplasia in familial adenomatous polyposis: a randomized clinical trial. *JAMA*. 2016;315:1266–1275.
105. Steinbach G, Lynch PM, Phillips RK, et al. The effect of celecoxib, a cyclooxygenase-2 inhibitor, in familial adenomatous polyposis. *N Engl J Med*. 2000;342:1946–1952.
106. Lynch PM, Ayers GD, Hawk E, et al. The safety and efficacy of celecoxib in children with familial adenomatous polyposis. *Am J Gastroenterol*. 2010;105:1437–1443.
107. Higuchi T, Iwama T, Yoshinaga K, Toyooka M, Taketo MM, Sugihara K. A randomized, double-blind, placebo-controlled trial of the effects of rofecoxib, a selective cyclooxygenase-2 inhibitor, on rectal polyps in familial adenomatous polyposis patients. *Clin Cancer Res*. 2003;9:4756–4760.
108. Iwama T, Akasu T, Utsunomiya J, Muto T. Does a selective cyclooxygenase-2 inhibitor (tiracoxib) induce clinically sufficient suppression of adenomas in patients with familial adenomatous polyposis? A randomized double-blind placebo-controlled clinical trial. *Int J Clin Oncol*. 2006;11:133–139.
109. Hallak A, Alon-Baron L, Shamir R, et al. Rofecoxib reduces polyp recurrence in familial polyposis. *Dig Dis Sci*. 2003;48:1998–2002.
110. Phillips RK, Wallace MH, Lynch PM, et al; FAP Study Group. A randomised, double blind, placebo controlled study of celecoxib, a selective cyclooxygenase 2 inhibitor, on duodenal polyposis in familial adenomatous polyposis. *Gut*. 2002;50:857–860.
111. West NJ, Clark SK, Phillips RK, et al. Eicosapentaenoic acid reduces rectal polyp number and size in familial adenomatous polyposis. *Gut*. 2010;59:918–925.
112. Bussey HJ, DeCosse JJ, Deschner EE, et al. A randomized trial of ascorbic acid in polyposis coli. *Cancer*. 1982;50:1434–1439.
113. DeCosse JJ, Miller HH, Lesser ML. Effect of wheat fiber and vitamins C and E on rectal polyps in patients with familial adenomatous polyposis. *J Natl Cancer Inst*. 1989;81:1290–1297.
114. Thomas MG, Thomson JP, Williamson RC. Oral calcium inhibits rectal epithelial proliferation in familial adenomatous polyposis. *Br J Surg*. 1993;80:499–501.
115. Balaguer F, Stoffel EM, Burke CA, et al; FAP-310 Investigators. Combination of sulindac and eflornithine delays the need for lower gastrointestinal surgery in patients with familial adenomatous polyposis: post hoc analysis of a randomized clinical trial. *Dis Colon Rectum*. 2022;65:536–545.
116. Samadder NJ, Kuwada SK, Boucher KM, et al. Association of sulindac and erlotinib vs placebo with colorectal neoplasia in familial adenomatous polyposis: secondary analysis of a randomized clinical trial. *JAMA Oncol*. 2018;4:671–677.
117. Lynch PM, Burke CA, Phillips R, et al. An international randomised trial of celecoxib versus celecoxib plus difluoromethylornithine in patients with familial adenomatous polyposis. *Gut*. 2016;65:286–295.
118. Crago AM, Chmielecki J, Rosenberg M, et al. Near universal detection of alterations in CTNNB1 and Wnt pathway regulators in desmoid-type fibromatosis by whole-exome sequencing and genomic analysis. *Genes Chromosomes Cancer*. 2015;54:606–615.
119. Nieuwenhuis MH, Lefevre JH, Bülow S, et al. Family history, surgery, and APC mutation are risk factors for desmoid tumors in familial adenomatous polyposis: an international cohort study. *Dis Colon Rectum*. 2011;54:1229–1234.
120. Koskenvuo L, Pitkäniemi J, Rantanen M, Lepistö A. Impact of screening on survival in familial adenomatous polyposis. *J Clin Gastroenterol*. 2016;50:40–44.
121. Desmoid Tumor Working Group. The management of desmoid tumours: a joint global consensus-based guideline approach for adult and paediatric patients. *Eur J Cancer*. 2020;127:96–107.
122. van Houdt WJ, Wei IH, Kuk D, et al. Yield of colonoscopy in identification of newly diagnosed desmoid-type fibromatosis with underlying familial adenomatous polyposis. *Ann Surg Oncol*. 2019;26:765–771.
123. Skapek SX, Anderson JR, Hill DA, et al. Safety and efficacy of high-dose tamoxifen and sulindac for desmoid tumor in children: results of a Children's Oncology Group (COG) phase II study. *Pediatr Blood Cancer*. 2013;60:1108–1112.
124. Chugh R, Wathen JK, Patel SR, et al; Sarcoma Alliance for Research through Collaboration (SARC). Efficacy of imatinib in aggressive fibromatosis: results of a phase II multicenter Sarcoma Alliance for Research through Collaboration (SARC) trial. *Clin Cancer Res*. 2010;16:4884–4891.
125. Penel N, Le Cesne A, Bui BN, et al. Imatinib for progressive and recurrent aggressive fibromatosis (desmoid tumors): an FNCLCC/French Sarcoma Group phase II trial with a long-term follow-up. *Ann Oncol*. 2011;22:452–457.
126. Kasper B, Gruenwald V, Reichardt P, et al. Imatinib induces sustained progression arrest in RECIST progressive desmoid tumours: final results of a phase II study of the German Interdisciplinary Sarcoma Group (GISG). *Eur J Cancer*. 2017;76:60–67.

Copyright © The American Society of Colon & Rectal Surgeons, Inc. Unauthorized reproduction of this article is prohibited.

127. Gounder MM, Mahoney MR, Van Tine BA, et al. Sorafenib for advanced and refractory desmoid tumors. *N Engl J Med*. 2018;379:2417–2428.
128. Gounder M, Ratan R, Alcindor T, et al. Nirogacestat, a γ-secretase inhibitor for desmoid tumors. *N Engl J Med*. 2023;388:898–912.
129. Azzarelli A, Gronchi A, Bertulli R, et al. Low-dose chemotherapy with methotrexate and vinblastine for patients with advanced aggressive fibromatosis. *Cancer*. 2001;92:1259–1264.
130. Skapek SX, Hawk BJ, Hoffer FA, et al. Combination chemotherapy using vinblastine and methotrexate for the treatment of progressive desmoid tumor in children. *J Clin Oncol*. 1998;16:3021–3027.
131. Gega M, Yanagi H, Yoshikawa R, et al. Successful chemotherapeutic modality of doxorubicin plus dacarbazine for the treatment of desmoid tumors in association with familial adenomatous polyposis. *J Clin Oncol*. 2006;24:102–105.
132. Kasper B, Raut CP, Gronchi A. Desmoid tumors: to treat or not to treat, that is the question. *Cancer*. 2020;126:5213–5221.
133. Crago AM, Denton B, Salas S, et al. A prognostic nomogram for prediction of recurrence in desmoid fibromatosis. *Ann Surg*. 2013;258:347–353.
134. Penel N, Chibon F, Salas S. Adult desmoid tumors: biology, management and ongoing trials. *Curr Opin Oncol*. 2017;29:268–274.
135. Nieuwenhuis MH, Mathus-Vliegen EM, Baeten CG, et al. Evaluation of management of desmoid tumours associated with familial adenomatous polyposis in Dutch patients. *Br J Cancer*. 2011;104:37–42.
136. Sinha A, Burns EM, Latchford A, Clark SK. Risk of desmoid formation after laparoscopic versus open colectomy and ileorectal anastomosis for familial adenomatous polyposis. *BJS Open*. 2018;2:452–455.
137. Sinha A, Tekkis PP, Gibbons DC, Phillips RK, Clark SK. Risk factors predicting desmoid occurrence in patients with familial adenomatous polyposis: a meta-analysis. *Colorectal Dis*. 2011;13:1222–1229.
138. Walter T, Zhenzhen Wang C, Guillaud O, et al. Management of desmoid tumours: a large national database of familial adenomatous patients shows a link to colectomy modalities and low efficacy of medical treatments. *United European Gastroenterol J*. 2017;5:735–741.
139. Sommovilla J, Liska D, Jia X, et al. IPAA Is more "desmoidogenic" than ileorectal anastomosis in familial adenomatous polyposis. *Dis Colon Rectum*. 2022;65:1351–1361.
140. Vitellaro M, Sala P, Signoroni S, et al. Risk of desmoid tumours after open and laparoscopic colectomy in patients with familial adenomatous polyposis. *Br J Surg*. 2014;101:558–565.
141. Xie M, Chen Y, Wei W, et al. Does ileoanal pouch surgery increase the risk of desmoid in patients with familial adenomatous polyposis? *Int J Colorectal Dis*. 2020;35:1599–1605.
142. Saito Y, Hinoi T, Ueno H, et al. Risk factors for the development of desmoid tumor after colectomy in patients with familial adenomatous polyposis: multicenter retrospective cohort study in Japan. *Ann Surg Oncol*. 2016;23(suppl 4):559–565.
143. Aelvoet AS, Struik D, Bastiaansen BAJ, et al. Colectomy and desmoid tumours in familial adenomatous polyposis: a systematic review and meta-analysis. *Fam Cancer*. 2022;21:429–439.
144. Elayi E, Manilich E, Church J. Polishing the crystal ball: knowing genotype improves ability to predict desmoid disease in patients with familial adenomatous polyposis. *Dis Colon Rectum*. 2009;52:1762–1766.
145. Filipe B, Baltazar C, Albuquerque C, et al. APC or MUTYH mutations account for the majority of clinically well-characterized families with FAP and AFAP phenotype and patients with more than 30 adenomas. *Clin Genet*. 2009;76:242–255.
146. Tieu AH, Edelstein D, Axilbund J, et al. Clinical characteristics of multiple colorectal adenoma patients without germline APC or MYH mutations. *J Clin Gastroenterol*. 2016;50:584–588.
147. Heinimann K, Thompson A, Locher A, et al. Nontruncating APC germ-line mutations and mismatch repair deficiency play a minor role in APC mutation-negative polyposis. *Cancer Res*. 2001;61:7616–7622.
148. Yamaguchi K, Komura M, Yamaguchi R, et al. Detection of APC mosaicism by next-generation sequencing in an FAP patient. *J Hum Genet*. 2015;60:227–231.
149. Spier I, Drichel D, Kerick M, et al. Low-level APC mutational mosaicism is the underlying cause in a substantial fraction of unexplained colorectal adenomatous polyposis cases. *J Med Genet*. 2016;53:172–179.
150. Bellido F, Pineda M, Aiza G, et al. POLE and POLD1 mutations in 529 kindred with familial colorectal cancer and/or polyposis: review of reported cases and recommendations for genetic testing and surveillance. *Genet Med*. 2016;18:325–332.
151. Giarola M, Stagi L, Presciuttini S, et al. Screening for mutations of the APC gene in 66 Italian familial adenomatous polyposis patients: evidence for phenotypic differences in cases with and without identified mutation. *Hum Mutat*. 1999;13:116–123.

Copyright © The American Society of Colon & Rectal Surgeons, Inc. Unauthorized reproduction of this article is prohibited.